



Best practices for **RADIO-GUIDED LUMBAR PUNCTURES**

Dr Adrien Felter, Radiologist, and Dr Tristan Thiry, Radiologist
Reference Centre for Neuromuscular Diseases
Radiology and Medical Imaging Department of Prof. Robert carlier
Assistance Publique des Hôpitaux de Paris

EDITORIAL

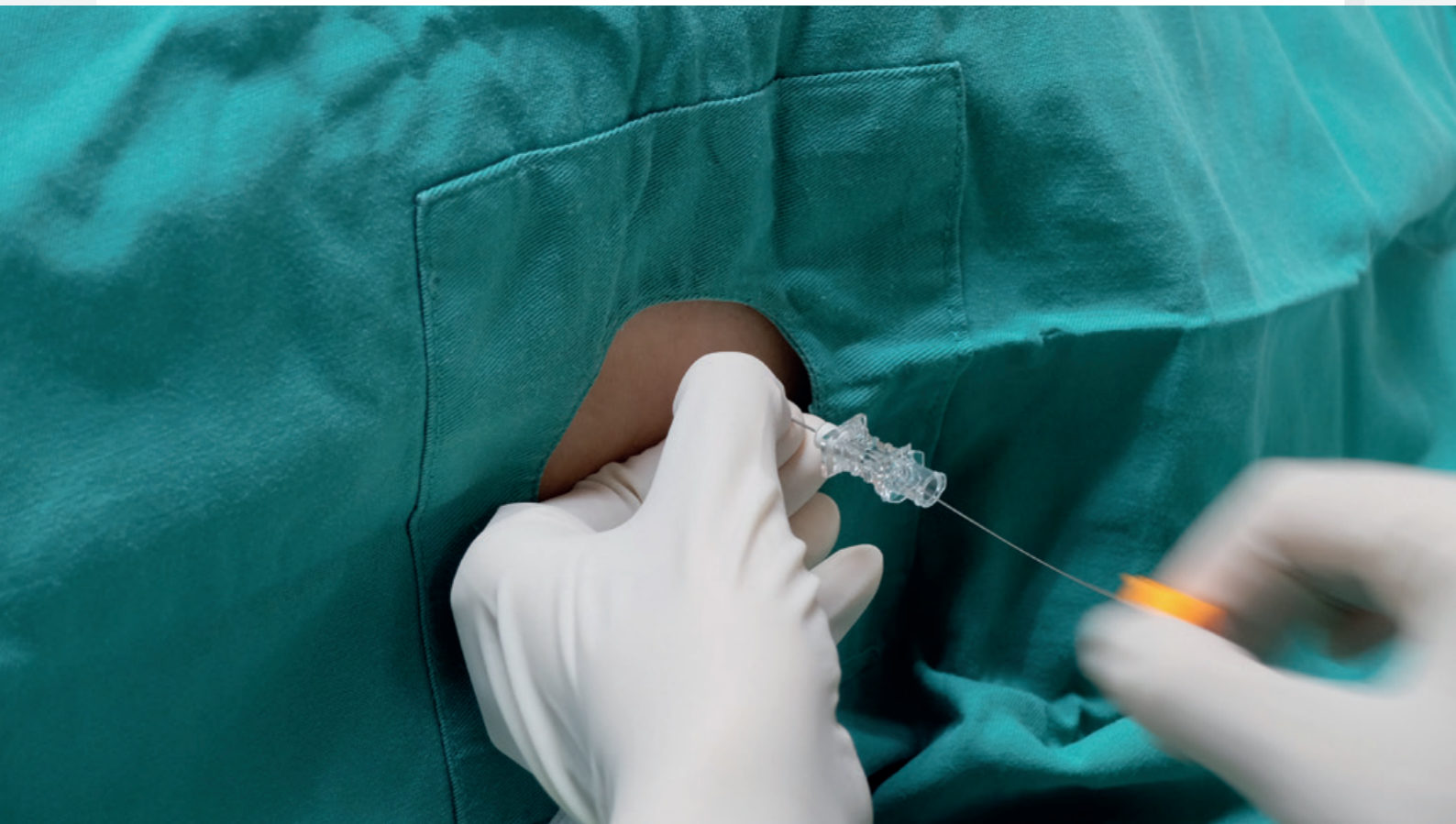Scoliotic deformities and **orthopaedic interventions**, such as vertebral arthrodesis, can make injections via lumbar puncture difficult and at times risky.

Technical advances in radiology guidance and **technical experience** make it possible today to find **reliable and accessible** solutions to carry out these procedures under safe conditions, in accordance with **good clinical practice**, as illustrated in this brochure.

In our experience, difficult lumbar punctures requiring radiology guidance have all been performed via the posterior interlaminar route, on the lumbar spine, under local anaesthesia, without needing to resort to a transforaminal trajectory or a cervical puncture.

The purpose of this brochure is to share good radiology guidance practices via **the expertise of the osteoarticular interventional radiology team at the Raymond-Poincaré Hospital of Garches.**

Adrien Felter
Tristan Thiry



RADIO-GUIDED LUMBAR PUNCTURES

TABLE OF CONTENTS

BEFORE PERFORMING A LUMBAR PUNCTURE 5

- Contraindications to lumbar puncture
- When should radiological guidance be used?
- When should pre-lumbar-puncture imaging be used?
- Which type of radiological guidance is most appropriate?

THE DAY OF THE PUNCTURE 9

- General recommendations on hygiene and asepsis
- Patient positioning
- Anxiety and pain management
- Choice of needle type

LUMBAR PUNCTURE UNDER ULTRASOUND GUIDANCE 13

LUMBAR PUNCTURE UNDER FLUOROSCOPIC GUIDANCE 17

LUMBAR PUNCTURE UNDER CT GUIDANCE 23

HOW TO REDUCE RADIATION EXPOSURE? 27

1. Contraindications to lumbar puncture

- Intracranial hypertension
- Arnold Chiari malformation (discussed contraindication)
- Tethered spinal cord (relative contraindication, to be discussed according to the imaging evaluation)
- Antithrombotics (except aspirin, HAS (Haute Autorité de Santé [French National Authority for Health]) 2013 guidelines)
- Anticoagulant therapy
- Major haemostasis disorders
- Infection or poor cutaneous state as regards the puncture area

2. When should radiological guidance be used?

- Scoliosis deformity with lumbar involvement
 - Scoliosis corresponds to a non-reducible three-dimensional spinal deformity.
 - The theoretical cutaneous landmarks via the palpation of the spinous process and the identification of the posterior iliac crests cannot be relied upon in the case of significant lumbar scoliosis deformity.

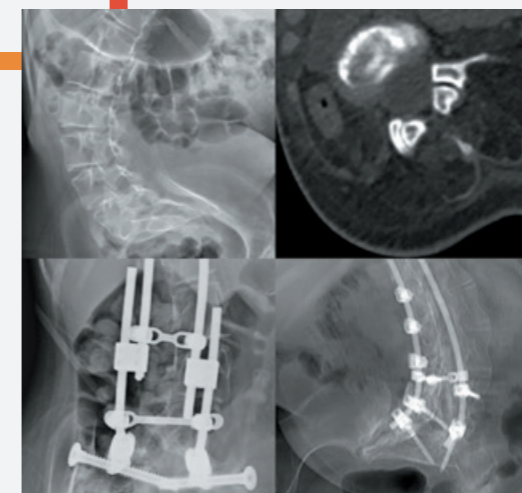

Figure 1: At the upper left: frontal X-ray of the lumbar spine with significant lumbar scoliosis with right convexity associated with a rotation and a rocking of the pelvis. At the upper right, same patient: CT scan in axial section showing the significant rotation of the vertebral body in the plane. This axial rotation, often underestimated by clinical examination, makes lumbar punctures without imaging guidance very difficult. Bottom left and right, other patients: the presence of vertebral instrumentation equipment or arthrodesis contraindicates the performing of a puncture without imaging guidance in view of the theoretical risk of infection in case of the contact of the needle with the surgical material.

- Operated scoliosis deformity: vertebral ankylosis
 - In progressive scoliosis, the purpose of spinal arthrodesis surgery is successful fusion of the vertebrae in order to obtain stabilisation of the deformities. This spinal fusion is often responsible for a more or less complete ossification of the interlaminar spaces.
 - Sometimes the narrow diameter of these residual spaces, and the significant angulation needed to arrive in the proper axis, render a successful puncture without guidance highly unlikely.
- Posterior spinal fusion equipment and spinal devices without transplant
 - There is a risk of infection of the arthrodesis equipment or device in the case of contact between the needle and the equipment.
 - The presence of posterior spinal surgical equipment at the lumbar level makes radiological guidance essential.

3. When should pre-lumbar-puncture imaging be used?

- We recommend systematically performing an imaging evaluation in these situations:
 - Progressive scoliosis with lumbar involvement
 - History of spinal surgery
 - History of failure of lumbar punctures without imaging guidance
- Methods for the imaging evaluation performed at the Raymond-Poincaré Hospital
 - **Front lumbar spine X-ray:** systematically initially performed to evaluate presence and X-ray visibility of the interlaminar space and the importance of the scoliosis. The lateral view of the lumbar spine does not provide any additional information.
 - **Lumbar ultrasound:** is performed in practice only in young children or thin patients with interlaminar spaces that are visible in X-rays.
 - **Lumbar spine CT scan:** performed in cases of a poor viewing of the interlaminar spaces on X-rays. Always check for the absence of a recent prior abdominal-pelvic or spinal CT scan in the history before prescribing a new imaging evaluation. An examination of the entire spine in a lumbar pre-puncture evaluation is not recommended.

4. Which type of radiological guidance is most appropriate?

- Recommended guidance equipment:
 - Fluoroscopy table with mobile C-arm or vascular radiology table allowing for the patient to be set up in a lateral decubitus position.
 - CT with interventional protocol (limitation of the delivered dose, laser-guided assistance, gantry tilt).
 - Recent ultrasound scan with wide frequency sensor (9-18 MHz).
- In summary:

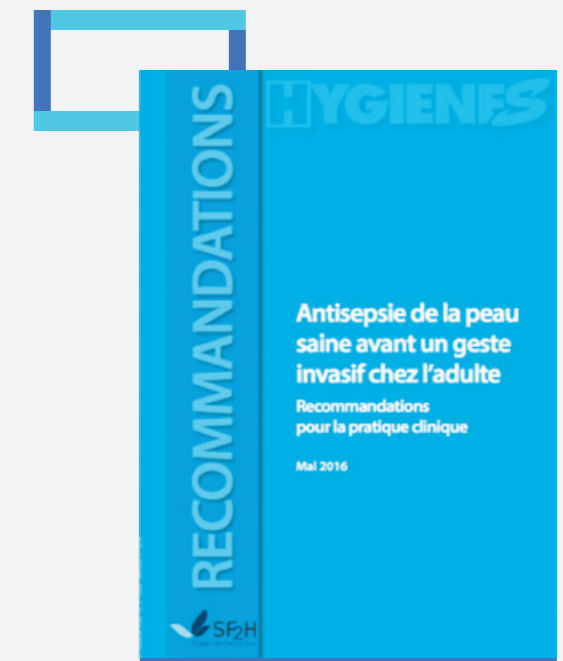	Fluoroscopic guidance	CT guidance	Ultrasound guidance
Difficulty (+ to +++)	+/++	+/++	++/+++
Learning curve	Average	Quick	Long
Usable for	<ul style="list-style-type: none"> • Any patient with a viewable interlaminar space in X-ray 	<ul style="list-style-type: none"> • Patient with a very narrow interlaminar space or not viewed in X-ray 	<ul style="list-style-type: none"> • Non-operated, thin patients with minimal scoliosis
Benefits	<ul style="list-style-type: none"> • Real-time guidance • Not very irradiating 	<ul style="list-style-type: none"> • Visualisation of all of the path of the needle • Very precise • Possibility of puncture through a very thin space 	<ul style="list-style-type: none"> • Real-time control of the needle path • Non-irradiating
Disadvantages	<ul style="list-style-type: none"> • Direct puncture path • Need a space large enough to be visualised • Visualisation can be hindered by projections of digestive gases 	<ul style="list-style-type: none"> • Difficult puncture if oblique path (poor visualisation of the needle) • Path of puncture difficult to modify if there is an error in the point of dermal entry • Patient exposure to radiation 	<ul style="list-style-type: none"> • Need for interlaminar space large enough to be visualised • Difficult in case of postoperative fibrosis

1. Patient positioning

- **The sitting position is the reference position for lumbar punctures.** Under radiology guidance, the sitting position is applicable in ultrasound scans but cannot be used for the guidance under scopic or CT control due to the design of the radiology equipment.
- **Under scopic and CT control, lateral decubitus is the best position.** Right or left side should be chosen according to scoliotic orientation and patient preference. Above all it is necessary to favour a comfortable position for the patient.
- **Procubitus (or ventral decubitus) position is not recommended;** in fact, the spontaneous discharge of the cerebrospinal fluid is rarely obtained in this position, and moving the patient into a lateral decubitus position must be carried out with the needle in place.
- In all cases, the patient's position should always be discussed with the patient. It is necessary to find a compromise between the patient's comfort, the approach for the puncture, and anticipate the position for collecting the cerebrospinal fluid before starting the puncture procedure.

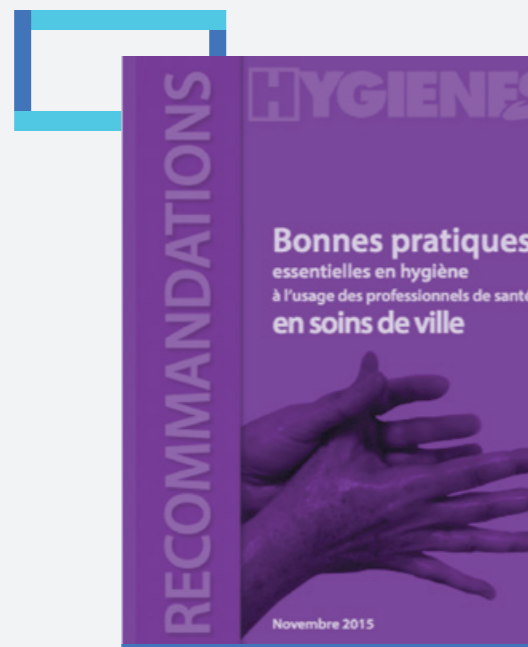
2. Cutaneous asepsis for the patient (French recommendations)

- **In the case of visibly clean skin:** cutaneous asepsis with 2 rounds of chlorhexidine alcohol with respect to the drying time between the two applications.
- **In case of visibly dirty skin:** first wash with mild soap, then perform cutaneous asepsis with 2 rounds chlorhexidine alcohol with respect to the drying time between the two applications.
- There are no longer any indications for antiseptic soap.



3. Practitioner hygiene

- Attire with short sleeves, short nails (1 mm or less), no jewellery on hands or wrists, short hair or hair pulled back with hygiene cap and surgical mask.
- Handwashing with mild soap at the start of the programme (then after if hands are visibly dirty or if using powdered gloves), to be carried out at least 10 minutes before the first alcohol-based surgical hand preparation, for a total washing duration of at least one minute with a rinse for one minute, followed by a complete wiping.
- Alcohol-based surgical hand preparation via friction before each puncture procedure with an initial disinfection (hands, wrists, forearms, elbows) until complete drying, immediately followed by a second disinfection of the hands and wrists until complete drying. Recommended duration of 3 minutes.
- **Single-use sterile gloves should be worn (non-sterile gloves should not be used).**
- Setting up of a sterile field with hole.





4. Anxiety and pain management

- Pain management is an essential step during any interventional procedure.
- There is a demonstrated relationship between anxiety and pain perception in both children and adults. A lessened anxiety leads to reduced perception of pain.
 - **For children, the puncture procedure must be carried out, if possible, in the presence of one of the parents.**
 - **Reassure the patient and the accompanying parties.**
 - **Explain the entire procedure to the patient and to the accompanying parties, the positioning, the local anaesthesia, and the possibility of speaking and breathing freely during the entire procedure.**
 - **Avoid the use of words with a negative or painful connotation (needle, injection, pain, etc.).**
 - **Use distractions (deep breathing techniques, videos on phone or tablet, music, etc.).**
 - **Always inform the patient that despite the use of local anaesthesia, perception of pressure and touch is most often preserved.**
- Use of lidocaine and prilocaine skin patches for short-term anaesthesia of the skin surface. They are placed on healthy and dry skin, without pressing the centre of the patch, at least 1 hour before the procedure, except for infants under the age of 3 months (apply for less than 1 hour) and in cases of atopic dermatitis (apply for less than 30 minutes).
- Local anaesthesia is obtained by lidocaine 5 mg/ml infiltration with a small needle (25G subcutaneous needle or less). **In our practice, local anaesthesia is systematically performed**, first of all to reassure the patient and parents. Indeed, some injections may be difficult, requiring the repositioning of the needle, which increases the duration of the procedure. In these particular cases, anaesthesia has a great benefit.
 - Maximum recommended doses of lidocaine in infiltration: 4.5 mg/kg (max. 200 mg) for adults and 3 mg/kg for children. For a child weighing 30 kg it equates to 90 mg or 18 ml max. of lidocaine 5 mg/ml or 4.5 ml of lidocaine 20 mg/ml.
 - The toxicity of lidocaine is correlated with the plasma concentration, which depends on the dose and the injection flow rate; the injection must be slow and fractionated, with a suction test prior to each injection (blood reflux contraindicates the injection).

- Inhalation of a mixture of nitrogen protoxide and oxygen, allowing for a short sedation with preserved consciousness in 2 to 3 minutes, without respiratory depression. The flow rate should be adapted to the patient. Adverse effects are common (~10%), mainly paradoxical excitement, nausea and vomiting, and profound sedation, and are rapidly reversible upon discontinuation of inhalation.

5. Choice of needle type

- Always adjust the length of the needle to the length of the puncture path. Collection of cerebrospinal fluid is easier with a short needle, however in some patients with thicker tissue a needle longer than the standard length of 9 cm must be employed.
- It is preferable to use a needle with a diameter of 22 Gauge or less, according to the operator's experience.
- Needles with a diameter of 20 Gauge are rigid and can be used in certain cases where the bone passage is narrow and requires bone "support", but are associated with a higher risk of post-lumbar puncture syndrome.

	 Conventional bevelled needles (Quincke)	 Atraumatic needles
Benefits	<ul style="list-style-type: none"> • Good sensations when penetrating tissue (post-operative fibrosis, aponeurosis, yellow ligament) • Use of the bevel allows changes in trajectory 	<ul style="list-style-type: none"> • Lower risk of post-lumbar puncture syndrome
Risks	<ul style="list-style-type: none"> • Higher risk of post-lumbar puncture syndrome 	<ul style="list-style-type: none"> • Difficult to use due to the absence of sensation when penetrating the tissue and the absence of change in trajectory • Inoperable in post-operative fibrosis

ULTRASOUND-GUIDED LUMBAR PUNCTURE

Ultrasound provides easily accessible guidance at the patient's bed, with real-time control of the entire needle's pathway, without exposure to ionising radiation. However, this type of guidance in scoliosis patients can be difficult because of the partial evaluation of the frontal scoliosis inflexion and the axial rotation of the vertebral bodies. In operated patients, post-operative fibrosis may render visualisation of the dural sac difficult.

1. Patient positioning

- **The ultrasound guidance can be performed in the lateral decubitus or sitting position.** The seated position allows for a better view of the scoliosis flexion and an easier orientation of the needle.
- In all cases the patient must be positioned with an anterior flexion of the torso so as to reduce lumbar lordosis as much as possible which increases the size of the interlaminar spaces.

2. Technical parameters

- In order to obtain an optimal view of the dural sac, it is necessary to adapt the technical parameters to each patient, mainly the settings of the gain, the frequency, and the position of the focal distance.

3. Identification of the interlaminar space

- A medial parasagittal longitudinal section adjacent to the spinous processes line shows lamina, yellow ligament, and more profoundly the dural sac. Identification of interlaminar space and dural sac is also feasible in the axial plane.

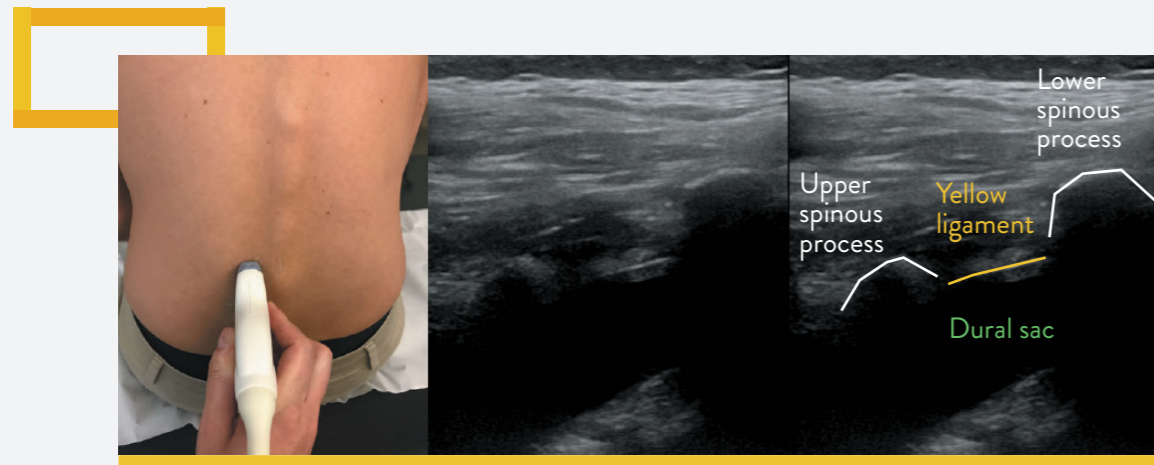


Figure 2: Ultrasound imaging in longitudinal plane.

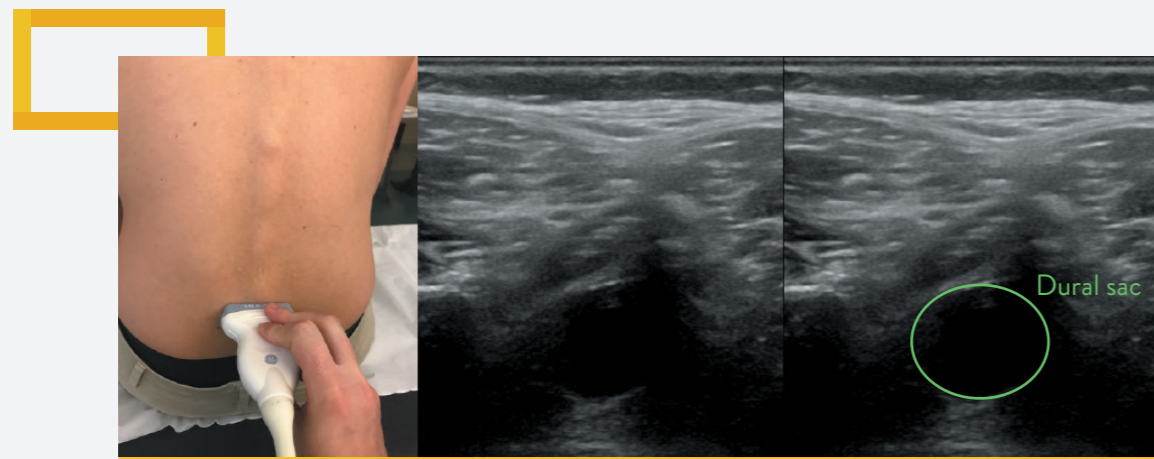


Figure 3: Ultrasound imaging in axial plane.

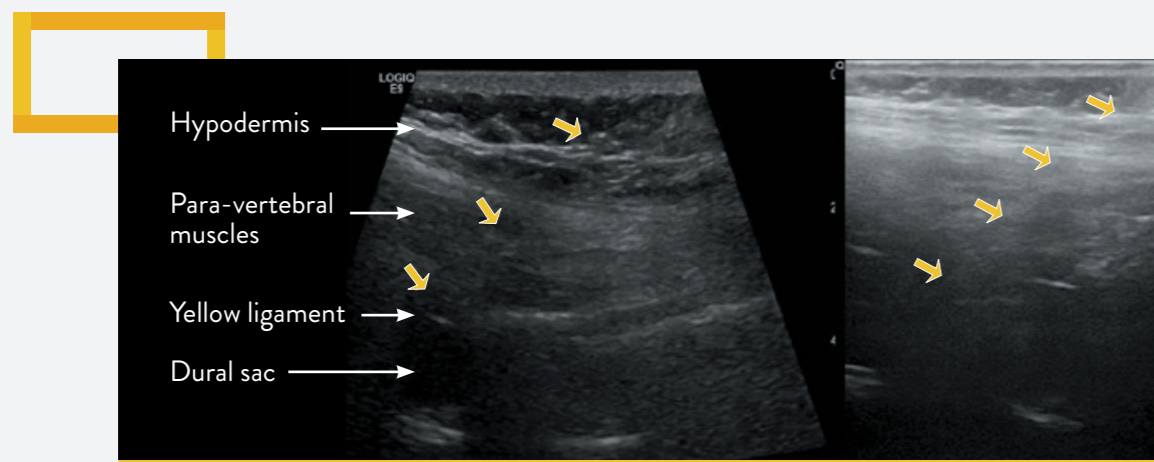


Figure 4: Examples of lumbar punctures under ultrasound control in longitudinal section in two different patients. The arrows indicate the needle is difficult to visualise due to the obliqueness of the puncture path.

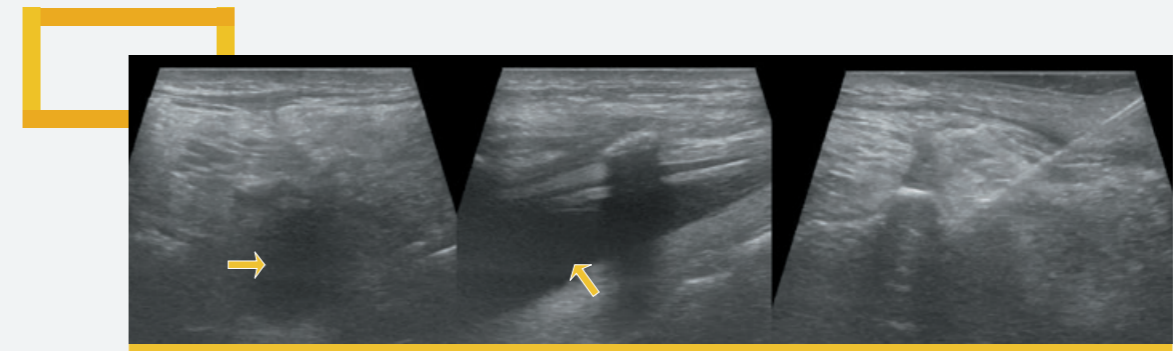


Figure 5: Example of puncture under ultrasound control.

Left: good visualisation of the anechoic dural sac (arrow) on axial section.

Centre: longitudinal section displays well-delineated dural sac (arrow). Bone surfaces of the spinous processes are visible as hyperechoic images with posterior acoustic shadowing.

Right: lateral dural puncture in cross-section with good visualisation of the needle path.

4. Experience at our centre

- Ultrasound-guided puncture is technically difficult in patients with prior surgery or with significant scoliosis, which represents the majority of our local patients.
- The use of this type of guidance is marginal in our practice.

1. Patient positioning

- Left or right lateral decubitus position.
- Ventral decubitus position possible.

2. Material and technical parameters

- An X-ray table with a mobile C-arm facilitates punctures on a patient in lateral decubitus position. The mobile C-arm can be oriented and thus adapted to the scoliotic inflection in order to obtain a strict frontal view of the vertebral bodies.
- The technical acquisition parameters (kilovoltage and mAs) must be adapted to the patient's body composition.

3. Identification of the interlaminar space

- The X-ray tube must be oriented so as to obtain a strict frontal view of the vertebral bodies. The pedicles must be symmetrical and the spinous processes must project equidistantly from the pedicles.
- The interlaminar space is discernable as a radiolucent area between the lamina.

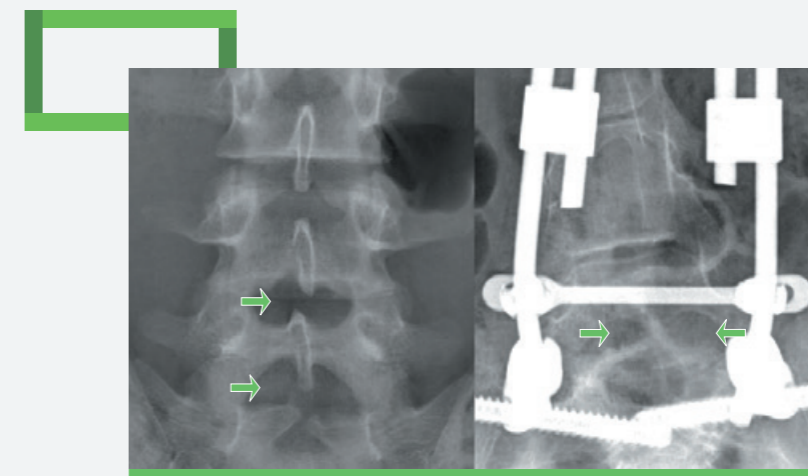


Figure 6: Pre-lumbar puncture X-rays
Left: absence of scoliosis and surgical material, easy identification of interlaminar spaces L4-L5 and L5-S1 (arrows).
Right: different patient, good visualisation of L4-L5 interlaminar space (arrows) despite scoliotic inflection and arthrodesis material.

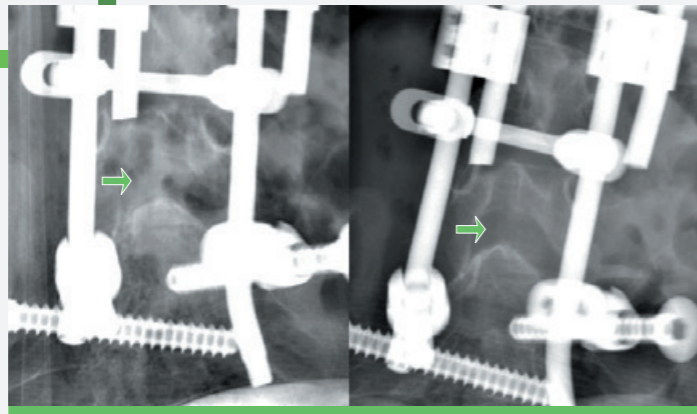


Figure 7: Pre-lumbar puncture X-rays
Left: L4-L5 interlaminar space poorly visualised due to digestive superposition (arrow).
Right: same patient, X-ray performed a little later, disappearance of digestive interposition and good visualisation of the L4-L5 interlaminar space (arrow) allowing an easy lumbar puncture under fluoroscopic control.

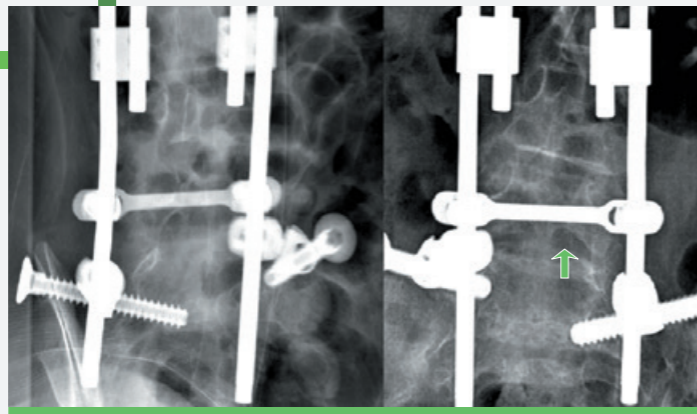


Figure 8: Pre-lumbar puncture X-rays
Left: L4-L5 interlaminar space poorly visualised due to rotation of vertebral bodies.
Right: inclination of the X-ray tube allowing frontal alignment of the vertebral bodies and a good visualisation of the interlaminar space L4-L5 (arrow).

- The puncture is performed using a frontal view with a direct path from the skin to the interlaminar space. The needle should be aligned in the X-ray beam axis. Oblique trajectories are not recommended for fluoroscopic guidance.

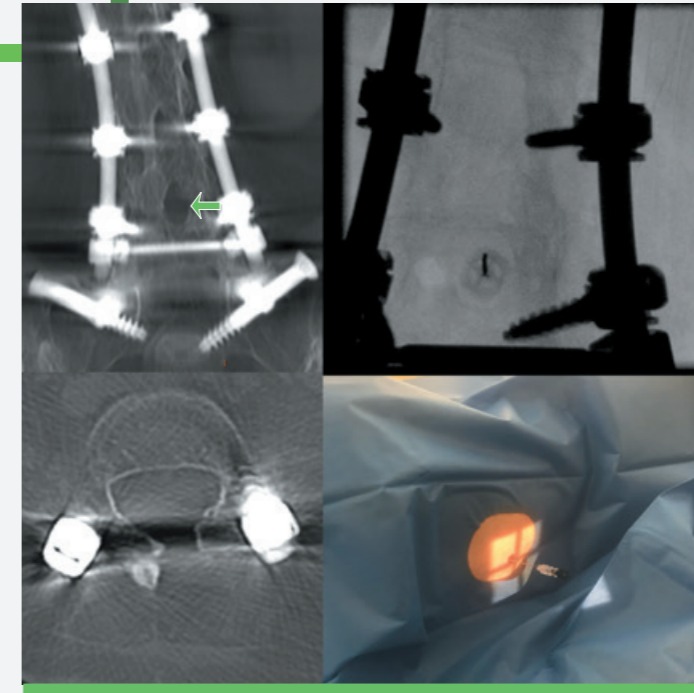
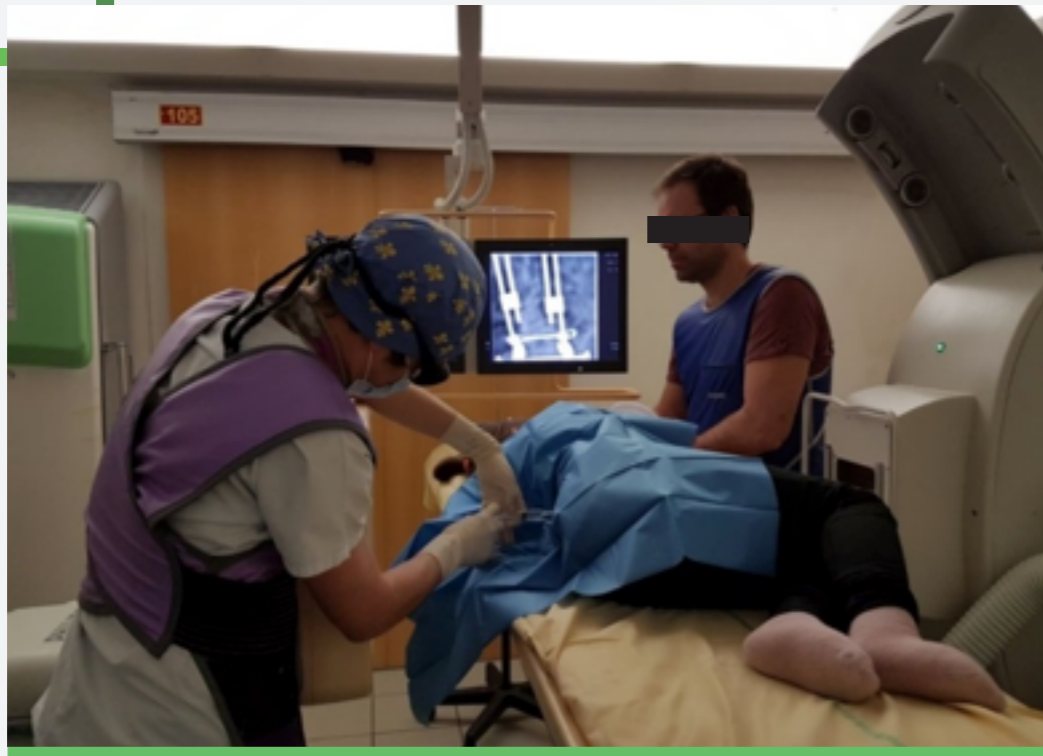

Figure 9: Example of intrathecal puncture in a 30-year-old patient with arthrodesis and extended spinal ankylosis.
Upper left: CT scan with thick coronal section reconstructions shows unfused L4-L5 interlaminar space (arrow).
Lower left: confirmation of the absence of bone fusion of the interlaminar space in the axial CT-scan reconstruction.
Upper right: puncture under fluoroscopic control in lateral decubitus, the scopic control per-procedure shows the good positioning of the needle in the interlaminar space L4-L5.
Lower right: use of the light centraliser to guide the trajectory of the needle. The shadow of the needle has been reduced to a symmetrical circle that makes it possible to ensure that the needle is well oriented on the axis of the X-ray beam, it is then sufficient to advance the needle carefully, by following this trajectory, until collection of the cerebrospinal fluid.

- Once the yellow ligament is crossed, progression millimetre by millimetre while removing the needle holder to check for the presence of a cerebrospinal fluid reflux.



• **Advantages of fluoroscopic guidance**

- Not much radiation
- Short examination duration
- Use of the rotating C-arm for frontal and lateral control
- Ascending or descending trajectory possible

• **Disadvantages of fluoroscopic guidance**

- Bone demineralisation
- Digestive interpositions

• **Limitations**

- Post-arthrodesis vertebral bone fusion with interlaminar space too small to be identified
- Requires experience of procedures under fluoroscopy (lumbar infiltrations+++)

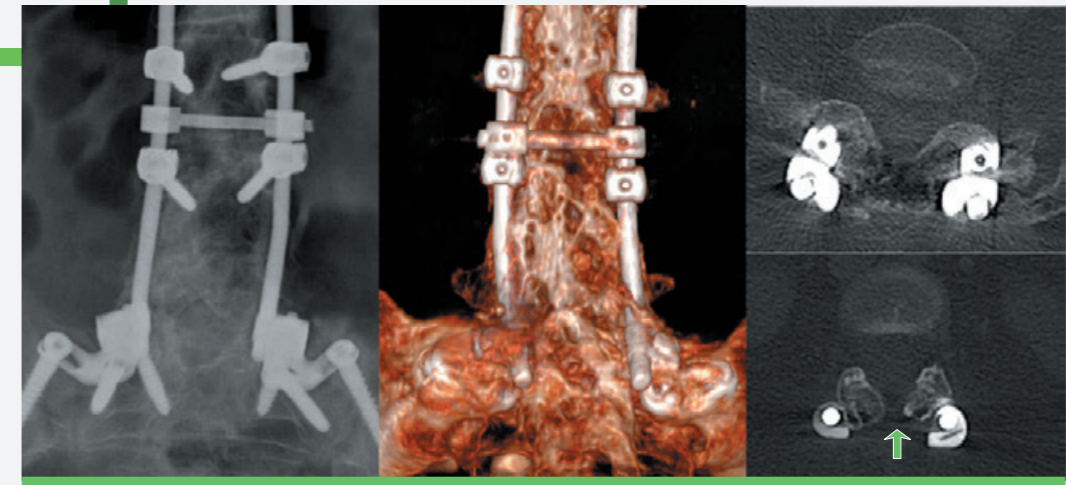


Figure 10: X-ray and CT lumbar puncture in a patient with significant ankylosis.

Left: L4-L5 interlaminar space aspect of atypical morphology.

Centre: CT scan in 3D reconstruction showing staged vertebral ankylosis. It should be noted that there is an underestimation of vertebral ankylosis in the X-ray on the left.

Upper right: CT scan at L4-L5 showing the absence of interlaminar space with continuous ankylosis making it impossible to puncture at this level.

Lower right: interlaminar space conserved at L2-L3 just below the crossbar of the arthrodesis making CT-guided puncture possible only because of the absence of visualisation of this space in radiography (arrow).

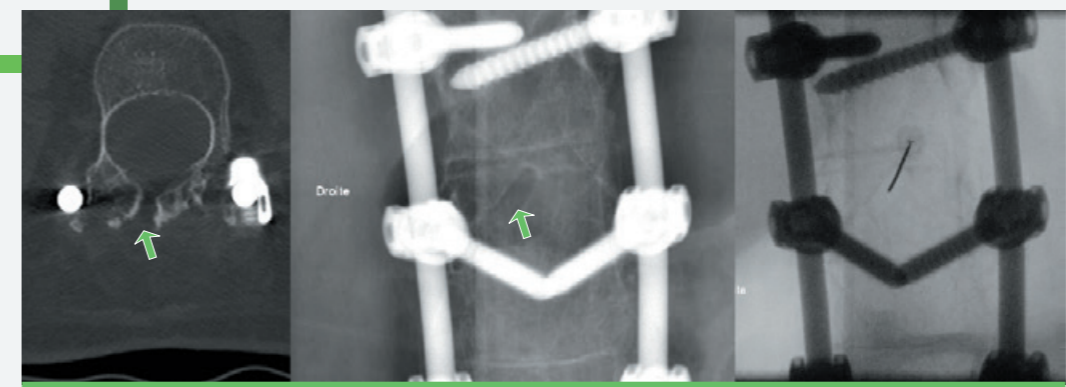


Figure 11: Pre-lumbar puncture X-ray and lumbar puncture.

Left: CT in axial section with single interlaminar space (arrow).

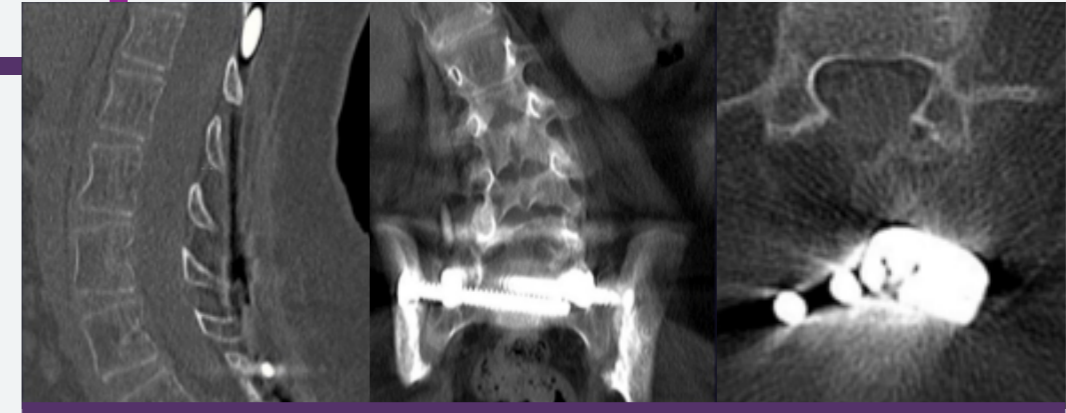Centre: frontal X-ray with good visualisation of interlaminar space due to cortical bone developed on the banks of space (arrow).

Right: scope marking for lumbar puncture with good visualisation of the interlaminar space.

4. Experience at our centre

- Fluoroscopic guidance is the most commonly used guiding method.
- The placement of the patient is essential: puncture should be performed on a spine that is perfectly “frontal” after adaptation of the positions of both patient and X-ray tube.
- Bone demineralisation and digestive gas interpositions make targeting difficult. It is necessary to use an X-ray film.
- If the procedure was performed with significant difficulty, or took a long time to perform (duration of fluoroscopy) and the patient had a bad experience, future injections need to be performed under CT guidance.

CT-GUIDED LUMBAR PUNCTURE



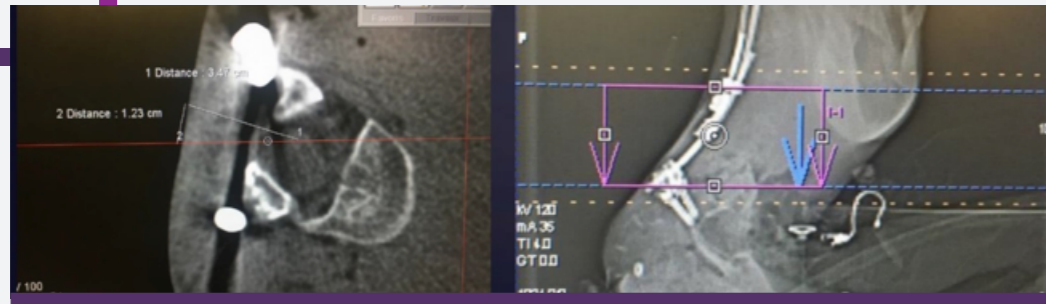
1. Patient positioning

- CT guidance allows positioning in the left or right lateral decubitus position.

2. Technical parameters

- Use of a sequential mode interventional CT scan programme with a CT scope enables control of puncture trajectory with only 3 slices, considerably reducing radiation exposure.

3. Identification of the interlaminar space



- CT pre-puncture helicoidal acquisition: as limited as possible.
- Identification of the skin using the laser (marking of the cutaneous point of entry, verification of the needle's axis).

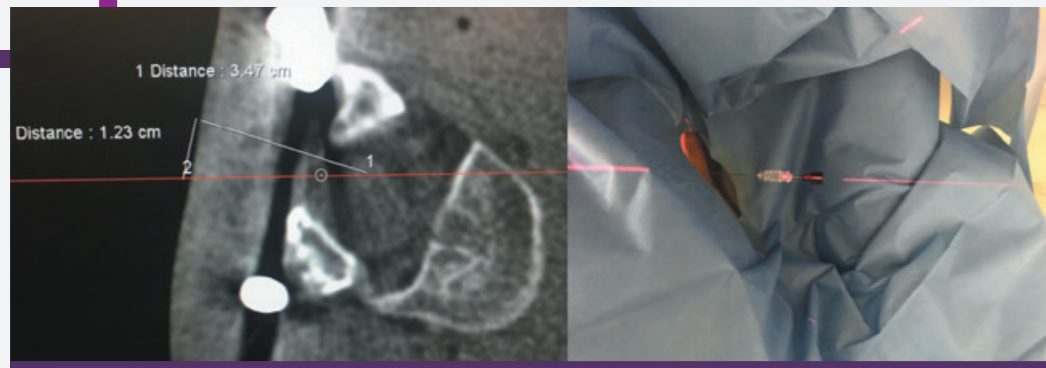
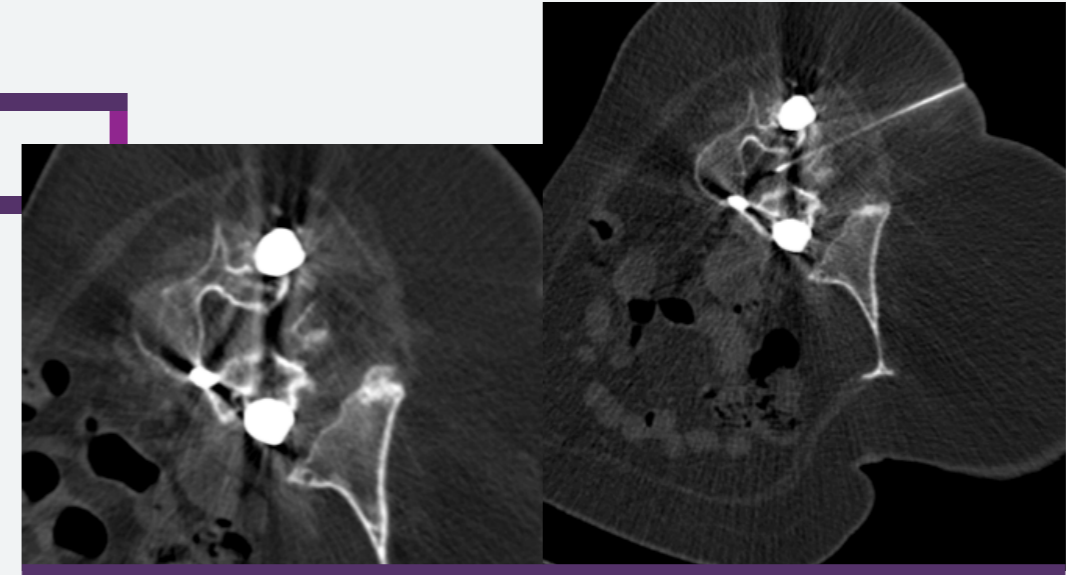


Figure 12: Skin detection using the laser.

Left: axial CT scan mark before lumbar puncture with tracking of the puncture path and the distance to be travelled. The red line represents the positioning of the laser guidance.

Right: bird's eye view of a lumbar puncture under CT guidance. Laser guidance allows the needle to be precisely positioned on the selected cut when marking.

- Verify the correct trajectory during needle progression sequential acquisitions or CT fluoroscopy.



• Advantages of CT guidance

- Reproducible
- Anatomical
- Easy interlaminar approach
- Analysis of the redistribution of visceral structures (essential for a potential foraminal route, etc.).

• Disadvantages of CT guidance

- Exposure to radiation often more important than radioscopy guidance.

- Sequential mode
 - Different from classical helicoidal acquisition
 - Ideally 3 slices
 - Needle location
 - Overlying and underlying cuts

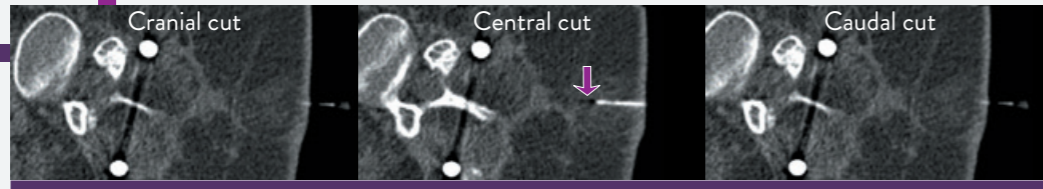


Figure 13: Scan slices in sequential interventional mode.
Seen with 3 slices: a cut centred on the needle in the centre, one above and one cut below. Target interlaminar space. Shadow cone facing the tip of the needle (arrow).

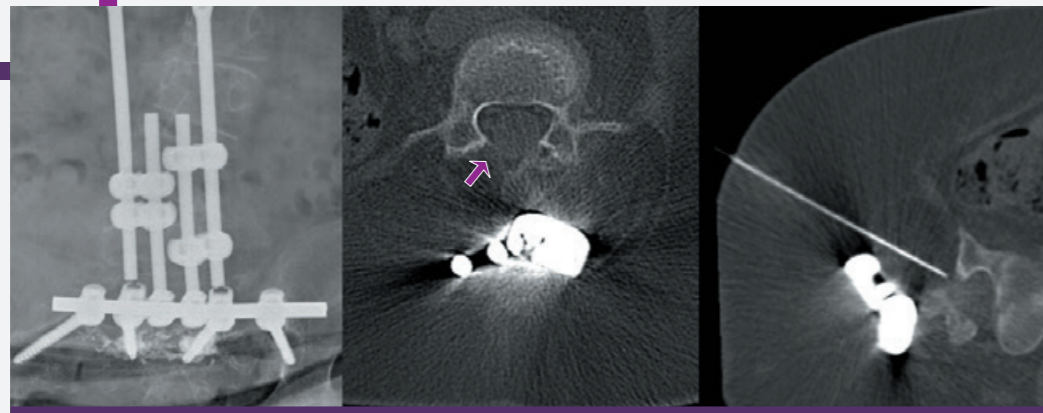


Figure 14: Acquisitions in sequential mode.
Left: pre-puncture registration radiography. Vertebral instrumentation equipment contraindicates puncture under scopic control.
Centre: axial CT section showing a large interlaminar space L3-L4 (arrow). Need for a lateral approach to avoid surgical material, only possible in this case under CT control.
Right: axial CT cut control when advancing the needle to the dural sac.

4. Experience at our centre

- CT scan in the most difficult cases: arthrodesis with large posterior bone fusion.
- Not always easy when the space is very narrow.

HOW TO REDUCE RADIATION EXPOSURE

An ultrasound should be performed to evaluate the possibility of US-guidance, especially in thin and non-operated patients.

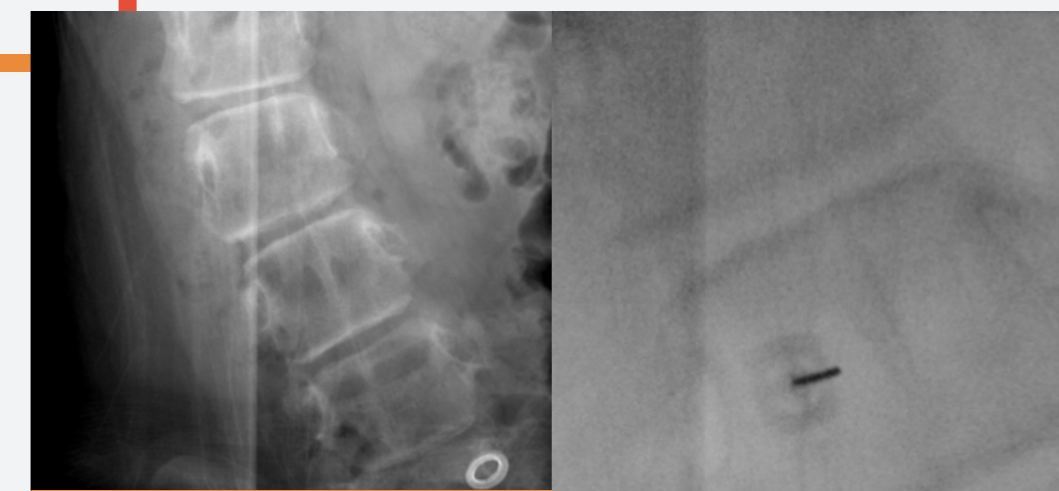The operator must use the technique that he/she is most comfortable with in order to reduce radiation exposure times when using CT or fluoroscopic guidance.

Analysis of patient history and of prior injections reduces the duration of the procedure.

Fluoroscopy	CT scan
• Flat panel detector system	• The most focused identification possible
• Progression of the needle with light-centring device	• Lower parameters
• Low fluoroscopy cadence	• Sequential mode
• Restricted diaphragm	• The most focused identification possible
• No systematic image of written form	• Illustrated practical cases

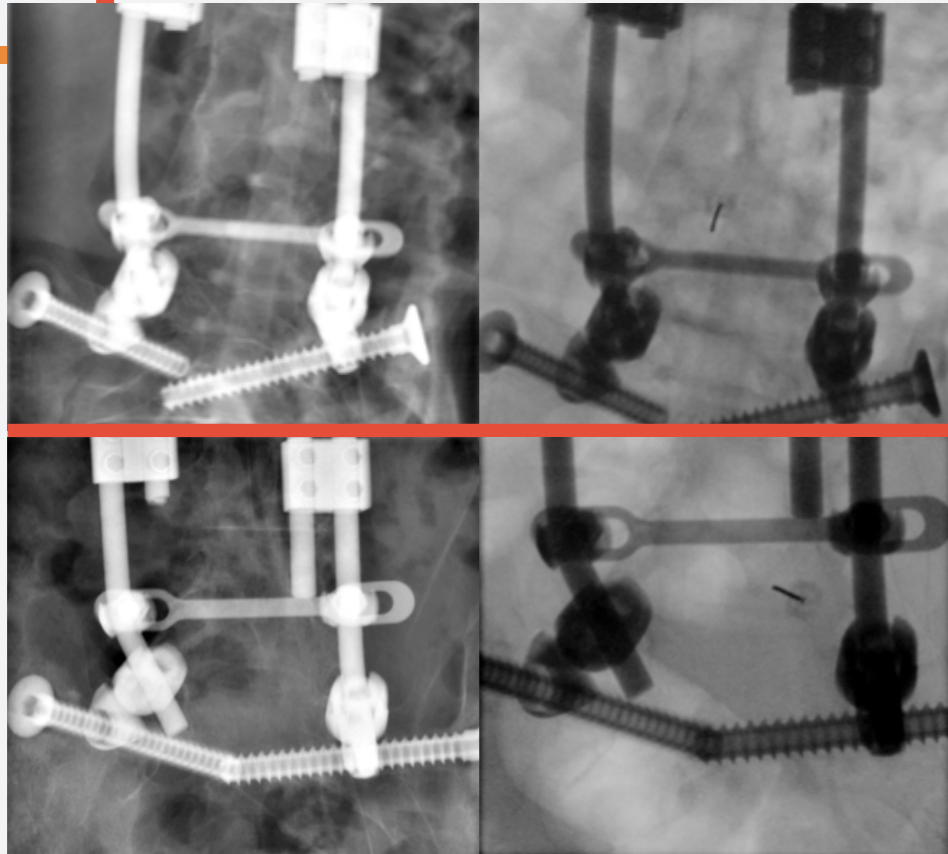
Illustrated practical cases

1. Scoliosis

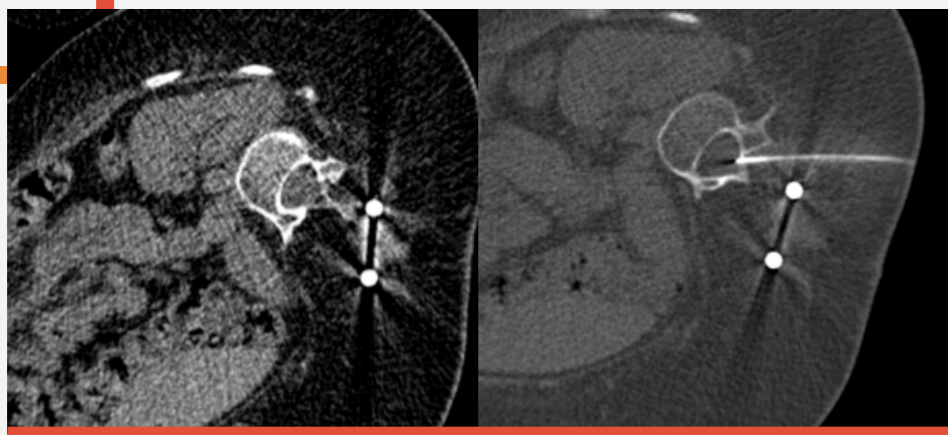


Adaptation of the diaphragm on the region of interest.

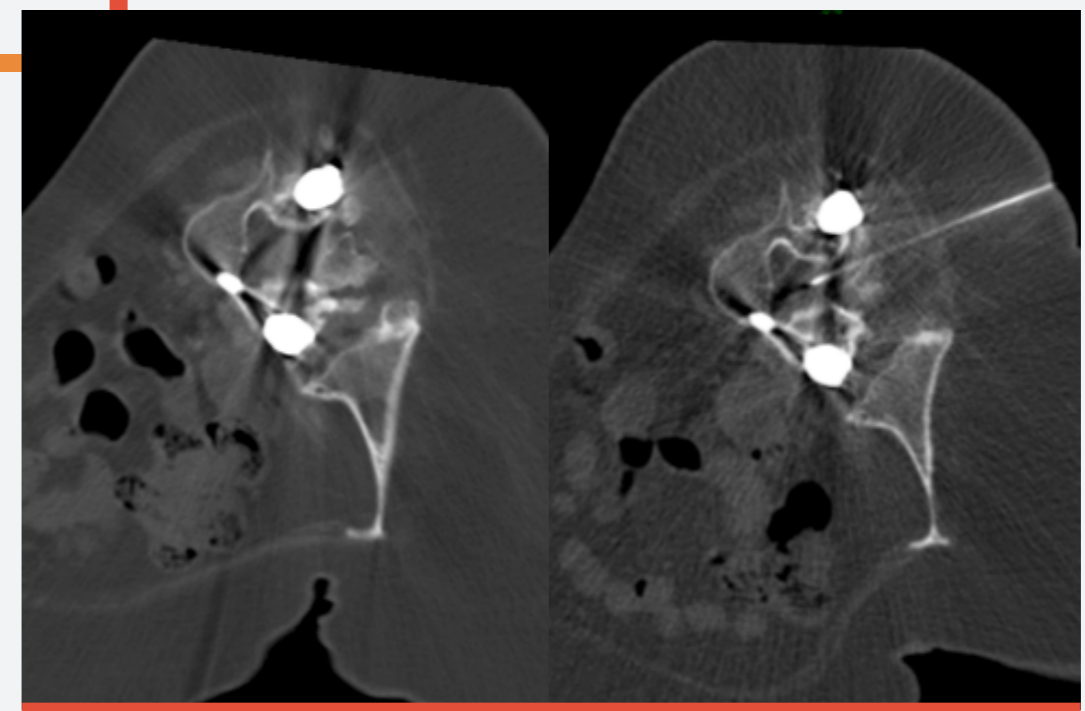
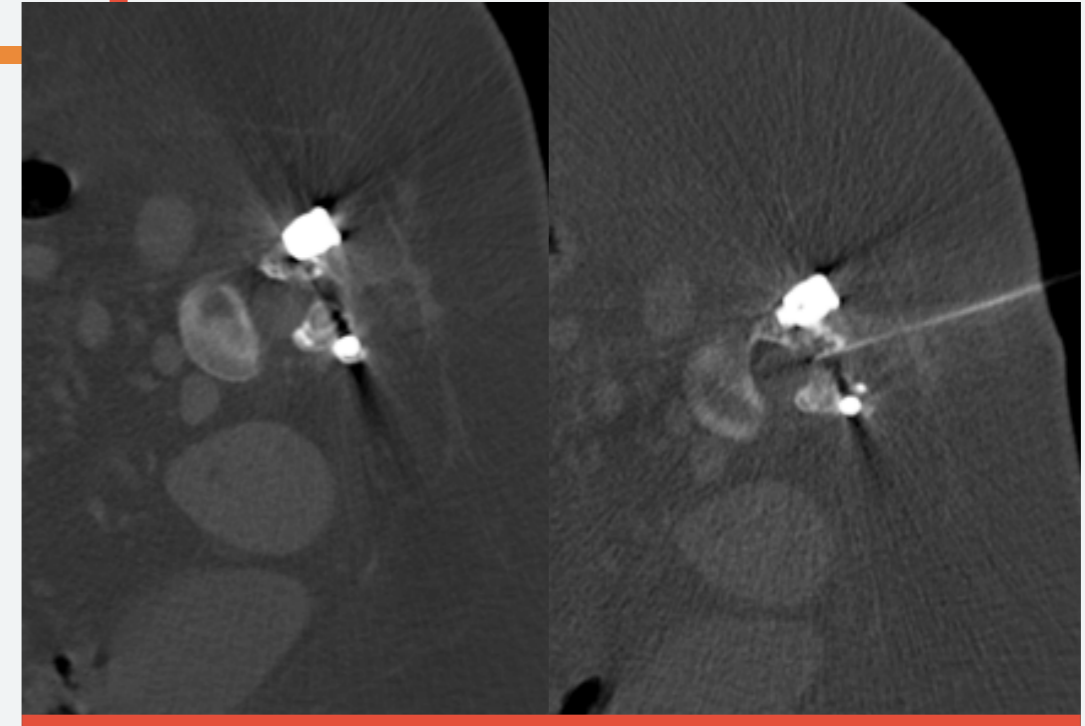
2. Instrumentation without bone graft; interlaminar space difficult to distinguish through the digestive gas interpositions.



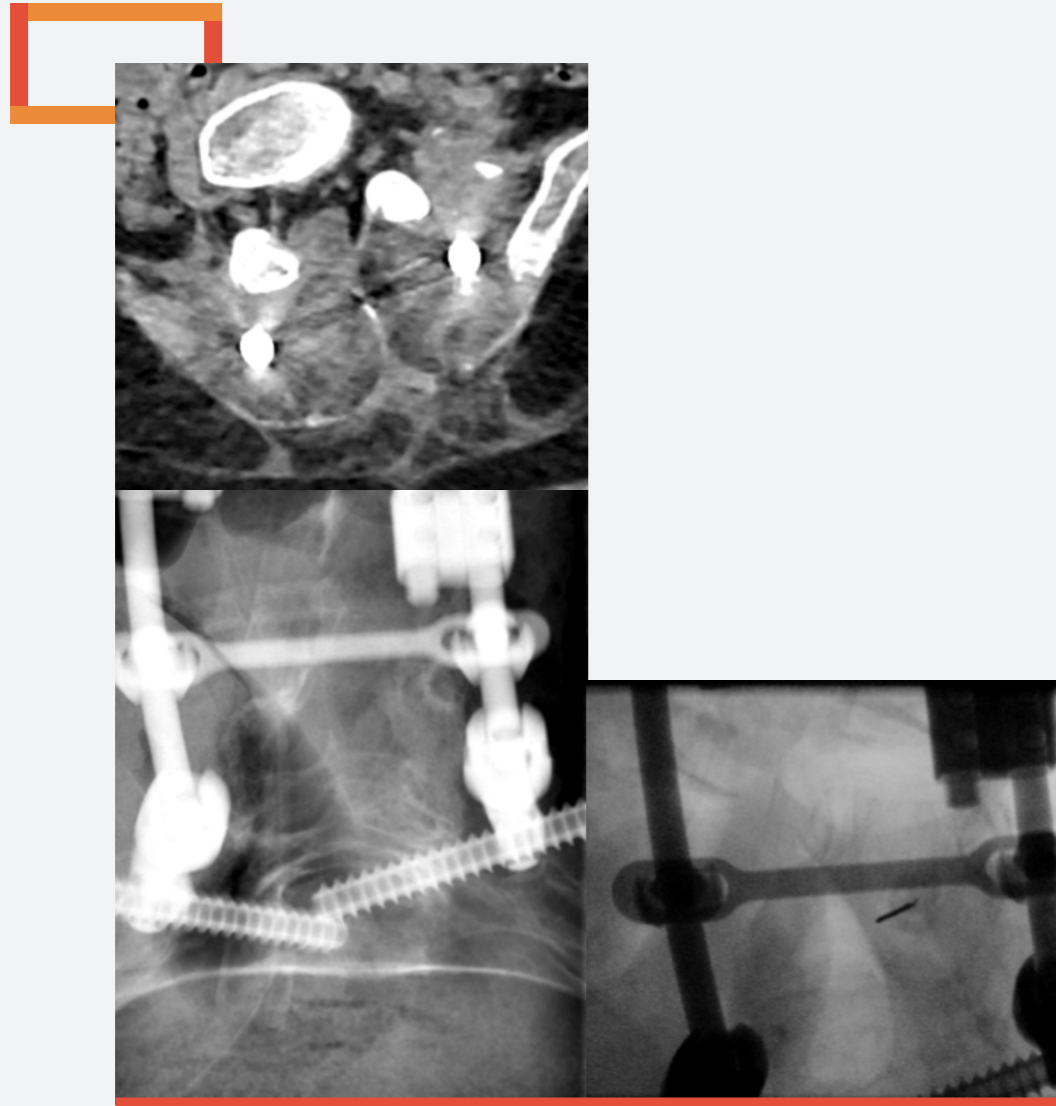
3. Instrumentation without bone graft, significant deformity, poor radiological viewing of spaces, CT scan needed.



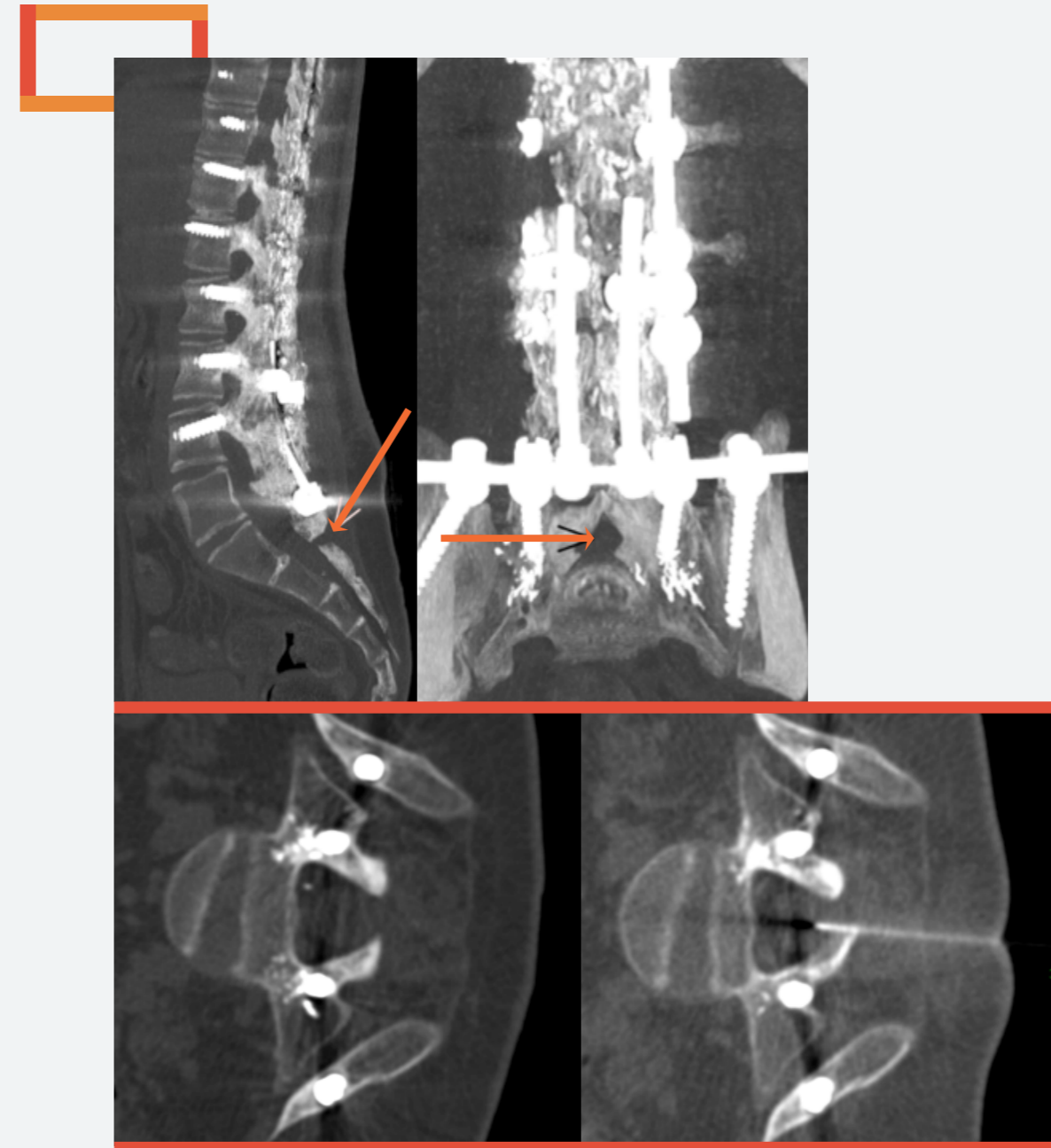
4 & 5. Large posterior bone fusion on spine with arthrodesis: persistence at only one level of a very narrow interlaminar space requiring CT scan and a posterolateral trajectory.



6. Dural sheath deviation necessitating a lateralised right puncture.



7. Patient with arthrodesis and complete posterior bone fusion without interlaminar space at lumbar level. Puncture at S2 level through a dehiscence posterior arch.



This guide is intended to share best practices of a French expert team.
The assessment and final decision for an individual patient is the responsibility of the treating physician.

Biogen Norway AS Vitaminveien 1A - 0485 Oslo - Biogen-47909 - Date of preparation: April 2020.



TOGETHER IN SMA™